

ORIGINAL ARTICLE

Ultrasound-Enhanced Systemic Thrombolysis for Acute Ischemic Stroke

Andrei V. Alexandrov, M.D., Carlos A. Molina, M.D., James C. Grotta, M.D., Zsolt Garami, M.D., Shiela R. Ford, R.N., Jose Alvarez-Sabin, M.D., Joan Montaner, M.D., Maher Saqqur, M.D., Andrew M. Demchuk, M.D., Lemuel A. Moyé, M.D., Ph.D., Michael D. Hill, M.D., and Anne W. Wojner, Ph.D., for the CLOTBUST Investigators*

ABSTRACT

BACKGROUND

From the Stroke Treatment Team, University of Texas–Houston Medical School, Houston (A.V.A., J.C.G., Z.G., S.R.F., A.W.W.); the Neurovascular Unit, Vall d'Hebron Hospital, Barcelona (C.A.M., J.A.-S., J.M.); the Division of Neurology, Department of Medicine, University of Alberta, Edmonton, Canada (M.S.); the Department of Clinical Neurosciences (A.M.D., M.D.H.) and the Departments of Community Health Sciences and Medicine (M.D.H.), University of Calgary, Calgary, Alta., Canada; and the Department of Biostatistics, School of Public Health, University of Texas, Houston (L.A.M.). Address reprint requests to Dr. Alexandrov at MSB 7.044, 6431 Fannin St., University of Texas, Houston, TX 77030, or at avalexandrov@att.net.

Transcranial Doppler ultrasonography that is aimed at residual obstructive intracranial blood flow may help expose thrombi to tissue plasminogen activator (t-PA). Our objective was to determine whether ultrasonography can safely enhance the thrombolytic activity of t-PA.

METHODS

We treated all patients who had acute ischemic stroke due to occlusion of the middle cerebral artery with intravenous t-PA within three hours after the onset of symptoms. The patients were randomly assigned to receive continuous 2-MHz transcranial Doppler ultrasonography (the target group) or placebo (the control group). The primary combined end point was complete recanalization as assessed by transcranial Doppler ultrasonography or dramatic clinical recovery. Secondary end points included recovery at 24 hours, a favorable outcome at three months, and death at three months.

RESULTS

A total of 126 patients were randomly assigned to receive continuous ultrasonography (63 patients) or placebo (63 patients). Symptomatic intracerebral hemorrhage occurred in three patients in the target group and in three in the control group. Complete recanalization or dramatic clinical recovery within two hours after the administration of a t-PA bolus occurred in 31 patients in the target group (49 percent), as compared with 19 patients in the control group (30 percent; $P=0.03$). Twenty-four hours after treatment of the patients eligible for follow-up, 24 in the target group (44 percent) and 21 in the control group (40 percent) had dramatic clinical recovery ($P=0.7$). At three months, 22 of 53 patients in the target group who were eligible for follow-up analysis (42 percent) and 14 of 49 in the control group (29 percent) had favorable outcomes (as indicated by a score of 0 to 1 on the modified Rankin scale) ($P=0.20$).

CONCLUSIONS

In patients with acute ischemic stroke, continuous transcranial Doppler augments t-PA-induced arterial recanalization, with a nonsignificant trend toward an increased rate of recovery from stroke, as compared with placebo.

*The centers and investigators participating in the CLOTBUST study are listed in the Appendix.

N Engl J Med 2004;351:2170-8.
Copyright © 2004 Massachusetts Medical Society.

HALF OF PATIENTS WHO HAVE HAD ischemic stroke remain moderately or severely disabled despite treatment with intravenous tissue plasminogen activator (t-PA).¹ Major reasons for incomplete recovery include a severe initial ischemic insult and slow and incomplete thrombolysis.^{2,3} Successful thrombolysis depends on the delivery of t-PA to the thrombus through residual blood flow around the arterial obstruction.^{4,5}

In experimental models, ultrasound has been shown to facilitate the activity of fibrinolytic agents within minutes of its exposure to a thrombus and to blood that contains t-PA.^{2,4-9} The mechanisms of ultrasound-enhanced thrombolysis include improved drug transport, reversible alteration of the fibrin structure, and increased binding of t-PA to fibrin^{2,4-9} when ultrasound frequencies ranging from kilohertz to those used in diagnostic ultrasonography are used.^{10,11} Although kilohertz frequencies penetrate better with minimal heating,^{12,13} a combination of t-PA and an experimental kilohertz-delivery system resulted in an excessive risk of intracerebral hemorrhage in patients with stroke.^{14,15} Diagnostic 2-MHz transcranial Doppler ultrasonography is routinely used in patients with stroke to obtain spectral velocity measurements in intracranial arteries.^{16,17} Transcranial Doppler can be aimed at the interface between residual flow and the intracranial thrombus by detecting abnormal wave forms.¹⁸

In a pilot study, we had found that complete recanalization coupled with dramatic clinical recovery from stroke occurred during transcranial Doppler monitoring of blood flow after t-PA infusion¹⁹ at rates that were higher than expected from studies of t-PA infusion alone.¹ We therefore performed a randomized trial with a predetermined sample size to evaluate rates of recanalization and clinical recovery with intravenous t-PA administered with or without continuous monitoring with transcranial Doppler ultrasonography. Our hypothesis was that continuous exposure to diagnostic ultrasonic waves would not result in an increased rate of symptomatic intracerebral hemorrhage and that such exposure might aid recanalization and clinical recovery from ischemic stroke. The purpose of this phase 2 trial was to determine the safety and biologic activity of this method and to obtain an estimate of the magnitude of the potential clinical benefit in order to plan a subsequent phase 3 efficacy trial.

METHODS

STUDY DESIGN

The Combined Lysis of Thrombus in Brain Ischemia Using Transcranial Ultrasound and Systemic t-PA (CLOTBUST) trial was a phase 2, multicenter, randomized clinical trial. Patients received standard intravenous t-PA therapy (i.e., 0.9 mg per kilogram of body weight [maximum, 90 mg], with 10 percent given as a bolus and 90 percent by continuous infusion). Therapy was initiated within three hours of the onset of symptoms of stroke, either with continuous monitoring with the use of transcranial Doppler ultrasonography (the target group) or with placebo monitoring (the control group).

The treating physicians administered t-PA (provided by Genentech) according to published criteria,¹ irrespective of the ultrasonographic findings. Patients who were eligible for the CLOTBUST trial also had evidence of obstructive residual flow in the middle cerebral artery, as observed on transcranial Doppler sonography before the t-PA bolus was given. An experienced physician-sonographer, who was not aware of the treatment assignment, diagnosed these occlusions with the use of previously validated criteria, including the Thrombolysis in Brain Ischemia (TIBI) flow-grading system.^{18,20,21} (On the TIBI scale, acute occlusions can present with absent, minimal, blunted, or dampened residual-flow wave forms.) Before the initiation of the study at each site, sonographers completed a computerized tutorial and passed (≥ 90 percent of the questions answered correctly) a validated multiple-choice examination on the interpretation of TIBI wave forms. In a prospective, multicenter validation study, our criteria for the detection of occlusions of the middle cerebral artery by transcranial Doppler ultrasonography had a rate of accuracy of greater than 90 percent, as compared with the results of invasive angiography.²² We used an insonation depth of 45 mm or more with the transcranial Doppler equipment for the identification of presumed proximal (i.e., M₁) occlusions of the middle cerebral artery and depths of 30 to 45 mm for presumed distal (i.e., M₂) occlusions. Eligible patients had abnormal flow through the middle cerebral artery, with a grade of 0, 1, 2, or 3 on the TIBI scale (a grade of 5 indicates complete recanalization), before the administration of a t-PA bolus.

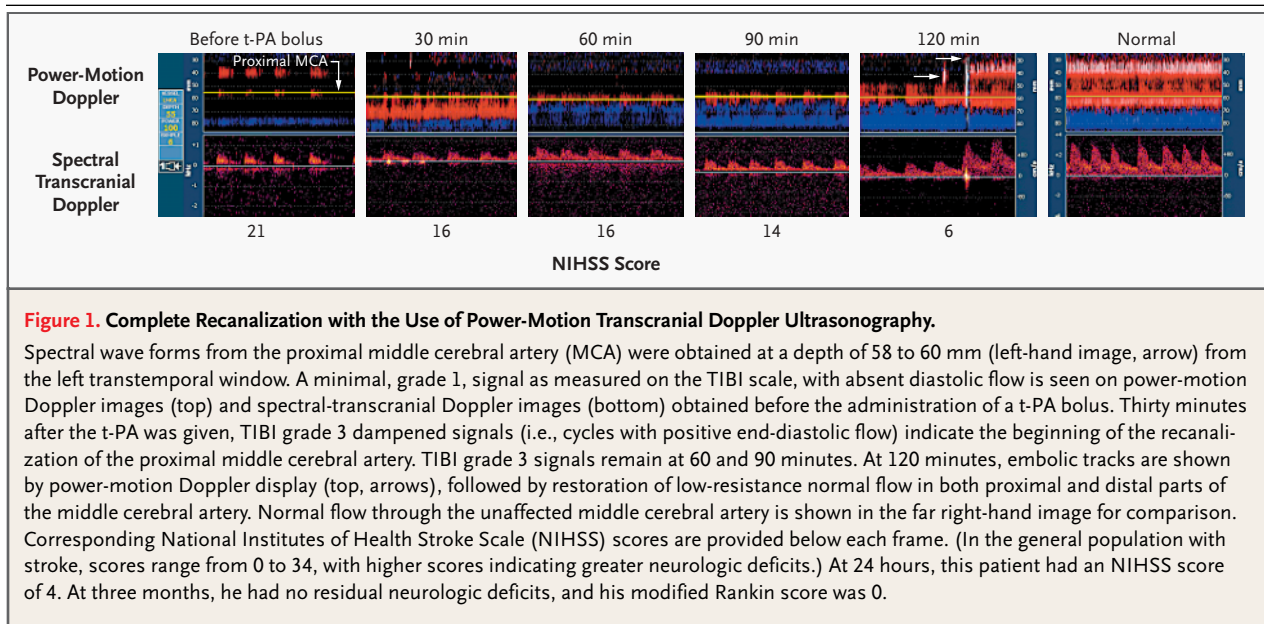
STUDY PROTOCOL

Approval was obtained from the institutional review board (IRB) at each clinical site. Written informed consent for participation in the trial was provided by all patients or their legal representatives. In all patients, transducers were positioned over the temporal bone at a constant angle with a standard head frame (Marc series, Spencer Technologies). The depth with the worst residual flow signal as measured on the TIBI scale was selected for display. All centers had power-motion Doppler units (PMD 100, Spencer Technologies). The use of other portable transcranial Doppler units (EZ-Dop, Multi-Dop T, DWL; 100 M, Multigon; and Companion III, Nicolet) was also permitted. All units were equipped with 2-MHz pulsed-wave diagnostic transducers approved by the Food and Drug Administration (FDA).

For each patient, after the head frame was positioned, sonographers opened a sealed envelope containing the random assignment to the target group or the control group. Randomization was not stratified by center. Randomization at a 1:1 ratio was performed in blocks of 10 patients at each site. In the target group, ultrasonographic monitoring was initiated before administration of the t-PA bolus and was continued for two hours. Emitted-power output was set at the maximal achievable level with selected insonation depths under the FDA-allowed threshold of 750 mW. Sample volumes, or

gates of insonation, were set at 3 to 6 mm for power-motion Doppler²³ units and 10 to 15 mm for all other single-channel transcranial Doppler units. For patients in the control group, the probe was re-plugged into an inactive channel with no continuous insonation. In both groups, sonographers muted the volume on transcranial Doppler units and turned the visual displays away from the treating physicians in order to keep the physicians blinded to the patients' study-group assignments. Further details of blinding procedures have been published previously.²⁴

In both groups, follow-up measurements were taken 30, 60, 90, and 120 minutes after the t-PA bolus was given. Arterial recanalization, as evident on transcranial Doppler wave forms, was determined with the use of the previously validated TIBI system.^{18,21} Sonographers determined that there was complete recanalization of the middle cerebral artery if a flow grade of 5 on the TIBI scale was identified (Fig. 1). Concomitant and persisting severe stenosis or occlusion of the proximal internal carotid artery was established by carotid duplex ultrasonography or by angiography. In patients with these conditions, complete recanalization of the middle cerebral artery was considered to have been achieved if on transcranial Doppler ultrasonography blunted but low-resistance wave forms were seen over both M_1 and M_2 segments,²¹ with an improvement in mean flow velocity to more than



20 cm per second. These criteria predict grade 3 flow, as measured on the angiographic Thrombolysis in Myocardial Infarction (TIMI) scale,²⁵ in the middle cerebral artery with a rate of accuracy above 90 percent.²¹ The TIMI scale is an angiographic scale that is applied to coronary and cerebral vessels, with grade 3 indicating unobstructed flow to affected tissues with or without proximal residual narrowing of the artery after thrombolysis. The principal investigator also reviewed digitized wave forms to confirm the readings from each study site. Partial recanalization was diagnosed if flow improved by one grade or more from the baseline but not to the level of grade 5 on the TIBI scale. Reocclusion was diagnosed if flow worsened by at least one grade.²⁶

The treating physicians assessed neurologic status without knowledge of random assignment and the results on transcranial Doppler monitoring at 30, 60, 90, and 120 minutes and at 24 hours with the use of the National Institutes of Health Stroke Scale (NIHSS). Modified Rankin scores were obtained at three months.

END POINTS

The prespecified primary-activity end point was the occurrence of complete recanalization according to TIBI criteria^{18,21} or early or dramatic clinical recovery from stroke.²⁴ Early clinical recovery was defined as a reduction of 10 or more points on the NIHSS, and dramatic recovery as a total NIHSS score of 3 or less within two hours after administration of the t-PA bolus.

If no early recanalization was observed, the CLOTBUST protocol permitted, at the discretion of the treating physician, rapid transport of the patient to the angiography unit for intraarterial intervention. A separate written informed-consent release, approved by the IRB at each site, was obtained in these circumstances. Participation in other clinical trials was prohibited.

The primary safety end point was intracerebral hemorrhage with clinical worsening (indicated by an NIHSS score of ≥ 4) within 72 hours of the onset of stroke. Secondary end points were clinical recovery at 24 hours, which was defined as a reduction of 10 or more on the NIHSS score or a total NIHSS score of 3 or less; a favorable outcome at three months (i.e., a modified Rankin score of 0 to 1); and death within three months after treatment.

STATISTICAL ANALYSIS

Before the trial began, we determined that a sample of 126 patients, with 63 in each of the two groups, was necessary for the study to detect a 20 percent absolute benefit in terms of the composite primary outcome at two hours after the t-PA bolus,²⁴ assuming a two-sided type I error of 0.05. Missing data on the outcome during the two hours of treatment were imputed by carrying forward the last available score. TIBI scores at 120 minutes were unavailable for seven patients (three in the control group and four in the target group) because these patients were undergoing cerebral angiography. In these cases, the TIBI scores at 60 minutes (five patients) or 90 minutes (two patients) were carried forward. Missing baseline glucose levels were imputed for six patients with the use of an internal-regression model that was based on age, sex, presence or absence of diabetes, time from the onset of symptoms to treatment, and the presence or absence of hypertension. Preplanned interim safety analyses evaluated the rate of symptomatic intracerebral hemorrhage after every 10 patients enrolled in the trial. Descriptive statistics were used to summarize the data. The equality of proportions was compared with the use of Fisher's exact test and the chi-square test. Logistic-regression models were used to test for interaction between variables and to provide risk estimates adjusted for the variables of treatment center, age, sex, NIHSS score, time from onset of symptoms to the administration of the t-PA bolus, baseline TIBI score, and glucose concentration. Conventional levels of statistical significance ($\alpha=0.05$) and two-sided tests were used in all analyses.

RESULTS

All 126 patients received treatment with intravenous t-PA: 63 were randomly assigned to receive continuous monitoring (the target group; median NIHSS score before the t-PA bolus, 16 points; 84 percent had scores of 10 or higher) and 63 were assigned to the control group (median NIHSS score, 17; 83 percent had scores of 10 or higher). The pretreatment characteristics of the two groups were similar (Table 1).

Overall, one-hour follow-up was complete for 99 percent of patients, two-hour follow-up for 96 percent, and three-month follow-up for 97 percent. No patients withdrew from the study. No serious

Table 1. Pretreatment Characteristics of Patients.*

Variable	Control Group (N=63)	Target Group (N=63)	P Value
Age (yr)	70±13	67±12	0.19
Systolic blood pressure (mm Hg)	158±22	160±22	0.68
Serum glucose (mg/dl)	146±69	138±61	0.58
Median NIHSS score	17	16	0.37
Occlusion of MCA (%)			
Proximal	70	79	0.41
Distal	30	21	0.41
Tandem 70–100% stenosis of proximal ICA (%)†	27	38	0.25
Median depth of residual flow signals (mm)	50	50	0.47
TIBI grade	1.6±1.1	1.6±0.9	0.86
Median time from onset of symptoms to t-PA bolus (min)	130	150	0.37
Treatment within 2 hr of onset (%)	43	27	0.09

* Plus-minus values are means ±SD. NIHSS scores range from 0 to 34, with higher scores indicating greater deficits. TIBI scores range from 0 to 5, with higher scores indicating completeness of recanalization. MCA denotes middle cerebral artery, and ICA internal carotid artery.

† Tandem indicates concomitant MCA and ICA obstruction.

Table 2. Recanalization, Clinical Recovery, and Reocclusion.*

Findings	Target Group (N=63)	Control Group (N=63)	P Value
	<i>no. (%)</i>		
Primary-activity end point	31 (49)	19 (30)	0.03
Complete recanalization within 2 hr	29 (46)	11 (18)	<0.001
Clinical recovery within 2 hr	18 (29)	13 (21)	0.4
Total NIHSS score ≤3	9 (14)	5 (8)	
Reduction in NIHSS score by ≥10 points	9 (14)	8 (13)	
Both clinical recovery and complete recanalization within 2 hr	16 (25)	5 (8)	0.02
Reocclusion within 2 hr†	11 (18)	14 (22)	0.7
Sustained complete recanalization at 2 hr	24 (38)	8 (13)	0.002

* The prespecified primary-activity end point was complete recanalization, early clinical recovery from stroke (defined as improvement to a total score on the NIHSS of ≤3 or a reduction in the score of ≥10) or both.

† Rates of reocclusion were determined in patients with complete and partial recanalization after administration of a t-PA bolus.

adverse effects were noted during ultrasonography. Reasons for incomplete follow-up included intubation due to the severity of clinical stroke and transfer to urgent diagnostic angiography. Nine patients in the target group (14 percent) and 11 in the con-

trol group (18 percent) underwent additional intra-arterial thrombolysis with mechanical manipulation of the thrombus; differences in outcomes between the groups were not influenced by these interventions. All patients whose condition worsened by 4 or more NIHSS points during the two hours after the bolus was given (five patients in each group [8 percent]) underwent urgent computed tomography (CT) of the head without the use of contrast material. These scans showed no intracerebral hemorrhage during exposure to ultrasonic waves.

Repeated CT scans or magnetic resonance images of the brain were obtained when clinically indicated between 5 and 72 hours after the onset of symptoms. Symptomatic intracerebral hemorrhage occurred in three patients in the target group and three in the control group (4.8 percent; difference in risk, 0.0 percent; 95 percent confidence interval for the difference in risk, -0.07 percent to 0.07 percent). No patient had intracerebral hemorrhage before undergoing intraarterial angiography. One symptomatic intracerebral hemorrhage occurred in each group after intraarterial procedures. When these patients were excluded, symptomatic intracerebral hemorrhage occurred in 2 of 62 patients (3 percent) in both groups.

Within two hours of the administration of the t-PA bolus, the primary combined end point was reached by 31 patients in the target group (49 percent) and 19 in the control group (30 percent; $P=0.03$; relative risk, 1.6; 95 percent confidence interval, 1.03 to 2.6). Complete recanalization occurred within two hours after the t-PA bolus in 29 patients in the target group (46 percent) and 11 in the control group (18 percent; $P<0.001$) (Table 2). Reocclusion occurred in 11 patients in the target group (18 percent) and 14 in the control group (22 percent). Complete recanalization was sustained at two hours after administration of the t-PA bolus in 24 patients in the target group (38 percent) and 8 patients in the control group (13 percent; $P=0.002$) (Fig. 2). All on-site readings were confirmed by central reading. The principal investigator reviewed all wave forms, irrespective of group assignment, for consistency of on-site interpretation with the use of TIBI flow-grade definitions. Clinical recovery occurred in 18 patients in the target group (29 percent) and in 13 in the control group (21 percent) within two hours of the t-PA bolus.

Patients who had complete recanalization at 120 minutes were more likely to have a complete recovery at 90 days (relative risk, 1.9; 95 percent con-

fidence interval, 1.1 to 3.0), with 22 percent more patients recovering completely, as compared with patients with partial or no recanalization. Complete recanalization at 120 minutes was predicted by assignment to active transcranial Doppler monitoring (relative risk, 2.6; 95 percent confidence interval, 1.4 to 4.8). In a logistic-regression model, complete recanalization was less likely among patients who had ipsilateral obstruction of the internal carotid artery (odds ratio, 0.35; 95 percent confidence interval, 0.14 to 0.90), a higher serum glucose level (odds ratio per additional 50 mg per deciliter, 0.57; 95 percent confidence interval, 0.37 to 0.99), and higher NIHSS scores (odds ratio per 5-point increase, 0.60; 95 percent confidence interval, 0.41 to 0.89). Although 49 percent of patients were treated and randomly assigned at a single hospital, there was no evidence of an interaction between site and treatment ($P=0.2$). Similarly, there was no evidence of an interaction between the treatment and the device (five types of transcranial Doppler units were used) ($P=0.8$).

Ultrasonographic monitoring was interrupted before two hours had passed after the t-PA bolus in the cases of 4 of the 20 patients who underwent intraarterial interventions. The randomization code was not broken in these cases, but the patients were excluded from secondary analyses. At 24 hours, 24 of 54 patients in the target group who were eligible for follow-up analysis (44 percent) and 21 of 52 in the control group (40 percent) had total NIHSS scores of 3 points or lower or had improved by 10 points or more ($P=0.7$).

Four patients did not return for the three-month follow-up visit (three patients in the control group, who had 24-hour NIHSS scores of 9, 10, and 15, and one in the target group, who had a 24-hour NIHSS score of 22). Patients who did not return for follow-up were excluded from the outcome analysis. At three months, 22 of the 53 patients eligible for analysis in the target group (42 percent) and 14 of the 49 eligible patients in the control group (29 percent) had modified Rankin scores of 0 or 1 (relative risk, 1.45; 95 percent confidence interval, 0.84 to 2.51; $P=0.2$). The mortality rates were 15 percent and 18 percent, respectively ($P=0.4$) (Fig. 3).

DISCUSSION

Our results show that continuous monitoring of intracranial occlusion with the use of 2-MHz, single-element pulsed-wave ultrasonography had a posi-

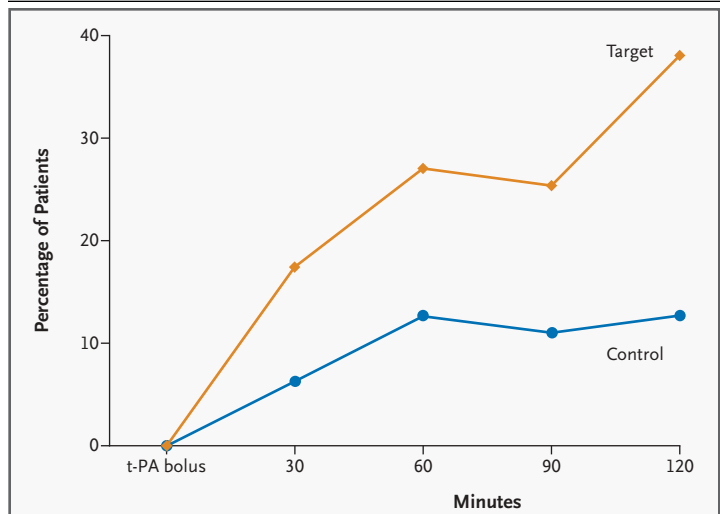


Figure 2. Rate of Sustained Complete Recanalization within Two Hours after Administration of a t-PA Bolus.

A trend toward the achievement of complete recanalization was observed over time with active treatment with the use of transcranial Doppler ultrasonography. Complete recanalization had occurred at 30 minutes after the t-PA bolus in 4 patients in the control group (6 percent; 95 percent confidence interval, 1.8 to 15.5) and in 11 patients in the target group (18 percent; 95 percent confidence interval, 9.0 to 29.1). At 60 minutes, 8 patients in the control group (13 percent; 95 percent confidence interval, 5.6 to 23.5) and 17 in the target group (27 percent; 95 percent confidence interval, 16.6 to 39.7) had complete recanalization. At 90 minutes, 7 patients in the control group (11 percent; 95 percent confidence interval, 4.6 to 21.6) and 16 in the target group (25 percent; 95 percent confidence interval, 15.3 to 27.9) had complete recanalization. At 120 minutes, 8 patients in the control group (13 percent; 95 percent confidence interval, 5.6 to 23.5) and 24 in the target group (38 percent; 95 percent confidence interval, 26.1 to 51.2) had complete recanalization. All 63 patients per group were accounted for at each time point.

tive effect on the primary-activity end point, with no increase in the rate of bleeding. Our findings indicate a biologic effect of diagnostic ultrasonography that aids systemic thrombolytic therapy in patients with acute ischemic stroke, since the combination of these techniques may facilitate clinical recovery. No patient left the trial despite monitoring with the head frame tightly fixed and ultrasonic waves delivered through the temporal bone at the full power settings that are allowed for diagnostic Doppler units. A previous study had shown that transmission of 2-MHz ultrasonic waves through the temporal bone of cadaver skulls caused an energy loss of 65 to 90 percent due to ultrasound accumulation in the bone.²⁷ Even these low energy levels appeared sufficient to enhance t-PA-induced thrombolysis with transcranial Doppler monitoring in an experimental skull model.¹¹

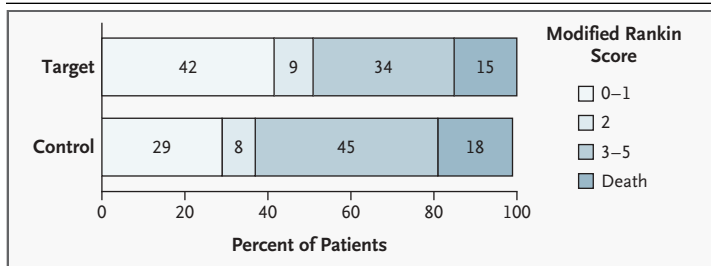


Figure 3. Outcomes at Three Months.

Favorable outcomes were defined as a score of 0 to 1 on the modified Rankin scale, indicating little or no disability. A total of 42 percent of patients in the target group who were eligible for follow-up and 29 percent of those in the control group met these criteria. Other outcomes included a modified Rankin score of 2 (9 percent in the target group vs. 8 percent in the control group); a score of 3 to 5 (34 percent in the target group vs. 45 percent in the control group); and death (15 percent in the target group vs. 18 percent in the control group).

In our randomized trial, there was a 38 percent rate of complete arterial recanalization that was sustained two hours after the administration of a t-PA bolus — a finding that is consistent with observations from the phase 1 trial.¹⁹ Previous studies also pointed to the possibility that diagnostic ultrasound equipment such as transcranial duplex units may enhance thrombolysis both with and without t-PA therapy.^{28,29} However, the small sample sizes in these studies precluded definitive conclusions from being drawn. Recent experimental work using ultrasound in the kilohertz range³⁰ points to a possibility that combined-frequency transducers may also be developed, although there is concern about safety with frequencies outside the range used in diagnostic ultrasonography.^{14,15}

Our data suggest that continuous monitoring with transcranial Doppler ultrasonography induced a detectable improvement of residual flow and probably converted partial recanalization with t-PA therapy into more complete early recanalization. The detectable flow improvement, in turn, produced a nonsignificant trend toward faster and near-complete clinical recovery from stroke within two hours after the administration of a t-PA bolus and complete recovery at three months. The National Institute of Neurological Disorders and Stroke Recombinant Tissue Plasminogen Activator (NINDS rt-PA) Stroke Study and a subsequent phase 4 trial demonstrated a rate of complete recovery from stroke at three months of 31 percent.^{1,31} In our trial, 29 percent of patients in the target group had early dramatic recovery shortly after they received the t-PA

bolus, an effect not previously detected in patients with stroke.³²

The relatively low rate of complete recovery at three months in our control group may be attributable to the exclusion of patients with lacunar strokes and to the presence of more severe stroke before treatment, as compared with the severity in patients in the NINDS rt-PA Stroke Study.¹ Also, the rate of complete recanalization in patients in the control group was low and similar to that with intravenous treatment with alteplase in a pilot study, involving patients with middle-cerebral-artery occlusions, in which outcome was measured by angiography.³³ Furthermore, a trend in baseline characteristics favored the control group, since more patients in that group were treated within two hours of the onset of symptoms and fewer patients had tandem obstructions of the internal carotid artery.

Previous studies do not provide estimates of the rate of recovery in patients with occlusions of the middle cerebral artery who were treated with t-PA within three hours after the onset of stroke. One objective of this study was to derive estimates of the sample size for a pivotal efficacy trial. On the basis of the rates of complete recovery at three months (42 percent and 29 percent in this trial), 274 patients per group will be needed for such a study to be able to demonstrate the effect of thrombolysis enhanced by ultrasonography on the outcome of stroke, with a two-sided α level of 0.05 and 90 percent power.

There are several limitations to this study. The assessment of the end point of early recanalization on transcranial Doppler ultrasonography could not be blinded, since the sonographers were aware of the group to which each patient was assigned. Our results are not easy to generalize owing to the extreme dependency on the skill of the operator who performs examinations with the use of transcranial Doppler equipment. Vascular tests that require the use of such equipment are among the most difficult to perform, and it is unrealistic to expect that an average clinician can quickly develop skills for the rapid location of occlusions with this nonimaging, hand-held method. This difficulty is evident from our trial, since only a small number of treatment centers had experienced sonographers on hand before t-PA therapy was begun. These skills, however, can be acquired through available tutorials in a reasonable length of time.

In conclusion, the enhancement of t-PA therapy with ultrasonography can be achieved safely and

noninvasively at the bedside. Our phase 2 trial demonstrates the potential of diagnostic ultrasonography to improve the efficacy of systemic therapy with t-PA in cases of acute ischemic stroke due to occlusion of the middle cerebral artery.

Supported by grants from the National Institute of Neurological Disorders and Stroke (1K23NS02229-01 and 1P50NS044227). Canadian sites were supported by the Canadian Institutes of Health Research and the Alberta Heritage Foundation for Medical Research. The CLOTBUST trial is an investigator-sponsored trial (protocol A2207s, Genentech) and is exempted from the Investigational New Drug status by the Food and Drug Administration. Spencer Technologies, Seattle, provided power-motion Doppler units at no charge and technical support for all participating study sites. DWL, Multigon, and Nicolet also provided portable equipment to hospitals in Houston at no charge.

Dr. Alexandrov reports having served as a consultant to Sanofi-Synthelabo and Bristol-Myers Squibb and having received lecture fees from Boehringer Ingelheim and grant support from Genentech.

A U.S. patent, "Therapeutic Method and Apparatus for Sonication to Enhance Perfusion Tissue" (no. 6733450), for which Dr. Alexandrov and Dr. Wojner are coinventors, was issued in May 2004; the patent is owned by the University of Texas. Dr. Grotta reports having served as a consultant to Encysive Pharmaceuticals and Alsium and having received lecture fees from ESP Pharma and grant support from the National Institute of Neurological Disorders and Stroke. A U.S. patent, "A Composition and Method for Treatment of Cerebral Ischemia" (no. 6500834), for which Dr. Grotta is one of the inventors, was issued in April 2000; the patent is owned by the University of Texas. Dr. Demchuk reports having served as a consultant to Sanofi-Synthelabo and having received lecture fees from Sanofi-Synthelabo and AstraZeneca and grant support from the Canadian Institutes of Health Research, the Alberta Heritage Foundation for Medical Research, the Canadian Stroke Network, the Calgary Regional Health Authority, the M.S.I. Foundation, the Canadian Health Region, the Heart and Stroke Foundation of Canada, and NIH NINDS. Dr. Hill reports having served as a consultant to Novo Nordisk and having received lecture fees from Sanofi-Synthelabo and grant support from Ono Pharmaceuticals.

APPENDIX

The CLOTBUST Investigators were as follows (numbers of patients enrolled are given in parentheses): *Memorial Hermann Hospital* (62) and *St. Luke's Episcopal Hospital* (8), Houston: F. Al-Senani, S. Burgin, S. Calleja, M. Campbell, C-I. Chen, O. Chernyshev, J. Choi, A. El-Mitwalli, R. Felberg, S. Ford, Z. Garami, W. Irr, J. Grotta, C. Hall, Y. Iguchi, J. Ireland, L. Labiche, M. Malkoff, L. Morgenstern, E. Noser, N. Okon, P. Piriya-wat, D. Robinson, H. Shaltoni, S. Shaw, K. Uchino, F. Yatsu; *Vall d'Hebron Hospital*, Barcelona (51): J. Alvarez-Sabin, J.F. Arenillas, R. Huertas, C. Molina, J. Montaner, M. Ribó, M. Rubiera, E. Santamarina; *University of Alberta Hospital*, Edmonton, Alta., Canada (3): M. Saqqur, N. Akhtar, F. O'Rourke, S. Hussain, A. Shuaib; *Calgary Foothills Hospital*, Calgary, Alta., Canada (2): E. Abdalla, A. Demchuk, K. Fischer, M.D. Hill, J. Kennedy, J. Roy, K.J. Ryckborst, M. Schebel.

REFERENCES

1. The NINDS rt-PA Stroke Study Group. Tissue plasminogen activator for acute ischemic stroke. *N Engl J Med* 1995;333:1581-7.
2. Francis CW. Ultrasound-enhanced thrombolysis. *Echocardiography* 2001;18:239-46.
3. Alexandrov AV, Burgin WS, Demchuk AM, El-Mitwalli A, Grotta JC. Speed of intracranial clot lysis with intravenous tissue plasminogen activator therapy: sonographic classification and short term improvement. *Circulation* 2001;103:2897-902.
4. Francis CW, Blinc A, Lee S, Cox C. Ultrasound accelerates transport of recombinant tissue plasminogen activator into clots. *Ultrasound Med Biol* 1995;21:419-24.
5. Blinc A, Kennedy SD, Bryant RG, Marder VJ, Francis CW. Flow through clots determines the rate and pattern of fibrinolysis. *Thromb Haemost* 1994;71:230-5.
6. Trubestein R, Engel C, Etzel F, Sobbe A, Cremer A, Stumpff U. Thrombolysis by ultrasound. *Clin Sci Mol Med Suppl* 1976;3:697s-698s.
7. Tachibana K, Tachibana S. Ultrasonic vibration for boosting fibrinolytic effects of urokinase in vivo. *Thromb Haemost* 1981;46:211. abstract.
8. Lauer CG, Burge R, Tang DB, Bass BG, Gomez ER, Alving BM. Effect of ultrasound on tissue-type plasminogen activator-induced thrombolysis. *Circulation* 1992;86:1257-64.
9. Kimura M, Iijima S, Kobayashi K, Furu-hata H. Evaluation of the thrombolytic effect of tissue-type plasminogen activator with ultrasound irradiation: in vitro experiment involving assay of the fibrin degradation products from the clot. *Biol Pharm Bull* 1994;17:126-30.
10. Blinc A, Francis CW, Trudnowski JL, Carstensen EL. Characterization of ultrasound-potentiated fibrinolysis in vitro. *Blood* 1993;81:2636-43.
11. Behrens S, Spengos K, Daffertshofer M, Schroeck H, Dempfle CE, Hennerici M. Transcranial ultrasound-improved thrombolysis: diagnostic vs. therapeutic ultrasound. *Ultrasound Med Biol* 2001;27:1683-9.
12. Akiyama M, Ishibashi T, Yamada T, Furu-hata H. Low-frequency ultrasound penetrates the cranium and enhances thrombolysis in vitro. *Neurosurgery* 1998;43:828-32.
13. Suchkova V, Siddiqi FN, Carstensen EL, Dalecki D, Child S, Francis CW. Enhancement of fibrinolysis with 40-kHz ultrasound. *Circulation* 1998;98:1030-5.
14. Daffertshofer M, Hennerici M. Ultrasound in the treatment of ischaemic stroke. *Lancet Neurol* 2003;2:283-90.
15. *Idem*. TRUMBI trial. *Cerebrovasc Dis* (in press).
16. Aaslid R, Markwalder TM, Nornes H. Noninvasive transcranial Doppler ultrasound recording of flow velocity in basal cerebral arteries. *J Neurosurg* 1982;57:769-74.
17. Sloan MA, Alexandrov AV, Tegeler CH, et al. Assessment: transcranial Doppler ultrasonography: report of the Therapeutics and Technology Assessment Subcommittee of the American Academy of Neurology. *Neurology* 2004;62:1468-81.
18. Demchuk AM, Burgin WS, Christou I, et al. Thrombolysis in Brain Ischemia (TIBI) transcranial Doppler flow grades predict clinical severity, early recovery, and mortality in patients treated with intravenous tissue plasminogen activator. *Stroke* 2001;32:89-93.
19. Alexandrov AV, Demchuk AM, Felberg RA, et al. High rate of complete recanalization and dramatic clinical recovery during tPA infusion when continuously monitored by 2-MHz transcranial Doppler monitoring. *Stroke* 2000;31:610-4.
20. Demchuk AM, Christou I, Wein TH, et al. Accuracy and criteria for localizing arterial occlusion with transcranial Doppler. *J Neuroimaging* 2000;10:1-12.
21. Burgin WS, Malkoff M, Felberg RA, et al. Transcranial Doppler ultrasound criteria for recanalization after thrombolysis for middle cerebral artery stroke. *Stroke* 2000;31:1128-32.
22. Saqqur M, Alexandrov AV, Hill MD, et al. Transcranial Doppler IMS criteria for rescue intra-arterial thrombolysis: multicenter experience from the Interventional Management Study. *Stroke* 2003;34:267. abstract.
23. Moehring MA, Spencer MP. Power M-mode Doppler (PMD) for observing cerebral blood flow and tracking emboli. *Ultrasound Med Biol* 2002;28:49-57.

24. Alexandrov AV, Wojner AW, Grotta JC. CLOTBUST: design of a randomized trial of ultrasound-enhanced thrombolysis for acute ischemic stroke. *J Neuroimaging* 2004;14:108-12.
25. The TIMI Study Group. The Thrombolysis in Myocardial Infarction (TIMI) trial: phase I findings. *N Engl J Med* 1985;312:932-6.
26. Alexandrov AV, Grotta JC. Arterial reocclusion in stroke patients treated with intravenous tissue plasminogen activator. *Neurology* 2002;59:862-7.
27. Grolimund P. Transmission of ultrasound through the temporal bone. In: Aaslid R, ed. *Transcranial Doppler sonography*. Wien, Germany: Springer-Verlag, 1986:10-21.
28. Eggers J, Koch B, Meyer K, König I, Seidel G. Effect of ultrasound on thrombolysis of middle cerebral artery occlusion. *Ann Neurol* 2003;53:797-800.
29. Cintas P, Le Traon AP, Larrue V. High rate of recanalization of middle cerebral artery occlusion during 2-MHz transcranial color-coded Doppler continuous monitoring without thrombolytic drug. *Stroke* 2002;33:626-8.
30. Suchkova VN, Baggs RB, Sahni SK, Francis CW. Ultrasound improves tissue perfusion in ischemic tissue through a nitric oxide dependent mechanism. *Thromb Haemost* 2002;88:865-70.
31. Albers GW, Bates VE, Clark WM, Bell R, Verro P, Hamilton SA. Intravenous tissue-type plasminogen activator for treatment of acute stroke: the Standard Treatment with Alteplase to Reverse Stroke (STARS) study. *JAMA* 2000;283:1145-50.
32. Caplan LR, Mohr JP, Kistler JP, Koroshetz W. Should thrombolytic therapy be the first-line treatment for acute ischemic stroke? Thrombolysis — not a panacea for ischemic stroke. *N Engl J Med* 1997;337:1309-10.
33. del Zoppo GJ, Poeck K, Pessin MS, et al. Recombinant tissue plasminogen activator in acute thrombotic and embolic stroke. *Ann Neurol* 1992;32:78-86.

Copyright © 2004 Massachusetts Medical Society.

IMAGES IN CLINICAL MEDICINE

The *Journal* welcomes consideration of new submissions for Images in Clinical Medicine. Instructions for authors and procedures for submissions can be found on the *Journal's* Web site at www.nejm.org. At the discretion of the editor, images that are accepted for publication may appear in the print version of the *Journal*, the electronic version, or both.