

Stroke

American Stroke
AssociationSM

JOURNAL OF THE AMERICAN HEART ASSOCIATION

A Division of American
Heart Association



Microbubble Administration Accelerates Clot Lysis During Continuous 2-MHz Ultrasound Monitoring in Stroke Patients Treated With Intravenous Tissue Plasminogen Activator

Carlos A. Molina, Marc Ribo, Marta Rubiera, Joan Montaner, Esteban Santamarina, Raquel Delgado-Mederos, Juan F. Arenillas, Rafael Huertas, Francisco Purroy, Pilar Delgado and José Alvarez-Sabín

Stroke 2006;37;425-429; originally published online Dec 22, 2005;

DOI: 10.1161/01.STR.0000199064.94588.39

Stroke is published by the American Heart Association, 7272 Greenville Avenue, Dallas, TX 75214
Copyright © 2006 American Heart Association. All rights reserved. Print ISSN: 0039-2499. Online
ISSN: 1524-4628

The online version of this article, along with updated information and services, is located on the World Wide Web at:

<http://stroke.ahajournals.org/cgi/content/full/37/2/425>

Subscriptions: Information about subscribing to Stroke is online at
<http://stroke.ahajournals.org/subscriptions/>

Permissions: Permissions & Rights Desk, Lippincott Williams & Wilkins, 351 West Camden Street, Baltimore, MD 21202-2436. Phone 410-5280-4050. Fax: 410-528-8550. Email:
journalpermissions@lww.com

Reprints: Information about reprints can be found online at
<http://www.lww.com/static/html/reprints.html>

Microbubble Administration Accelerates Clot Lysis During Continuous 2-MHz Ultrasound Monitoring in Stroke Patients Treated With Intravenous Tissue Plasminogen Activator

Carlos A. Molina, MD, PhD; Marc Ribo, MD, PhD; Marta Rubiera, MD; Joan Montaner, MD, PhD; Esteban Santamarina, MD; Raquel Delgado-Mederos, MD; Juan F. Arenillas, MD, PhD; Rafael Huertas, MD; Francisco Purroy, MD; Pilar Delgado, MD; José Alvarez-Sabín, MD, PhD

Background and Purpose—We sought to evaluate the effects of administration of microbubbles (MBs) on the beginning, speed, and degree of middle cerebral artery (MCA) recanalization during systemic thrombolysis and continuous 2-MHz pulsed-wave transcranial Doppler (TCD) monitoring.

Methods—We evaluated 111 patients with acute stroke attributable to MCA occlusion treated with intravenous tissue plasminogen activator (tPA). Thirty-eight patients were treated with tPA plus continuous 2-hour TCD monitoring plus 3 doses of 2.5 g (400 mg/mL) of galactose-based MBs given at 2, 20, and 40 minutes after tPA bolus (MB group). These patients were compared with 73 patients who were allocated to receive tPA plus continuous 2-hour TCD ultrasound (US) monitoring (tPA/US group) or tPA plus placebo monitoring (tPA group), most of whom were enrolled in a previous study of US-enhanced thrombolysis. The beginning, degree, and time to maximum completeness of recanalization during the first 2 hours of tPA bolus were recorded.

Results—Median prebolus National Institutes of Health Stroke Scale (NIHSS) score was 18. Eighty patients (72%) had a proximal and 31 (28%) a distal MCA occlusion on TCD. Thirty-seven patients (33%) received tPA/US, 38 (34%) received tPA/US/MB, and 36 (32%) were treated with tPA alone. Stroke severity, time to treatment, location of MCA occlusion, and presence of carotid artery disease were similar among groups. Two-hour recanalization was seen in 14 (39%), 25 (68%), and 27 patients (71%) in the tPA, tPA/US, and tPA/US/MB groups, respectively ($P=0.004$). Two-hour complete recanalization rate was significantly ($P=0.038$) higher in the tPA/US/MB group (54.5%) compared with tPA/US (40.8%) and tPA (23.9%) groups. The time to beginning of recanalization after tPA bolus was 26 ± 18 minutes in the tPA/US group and 19 ± 12 minutes in the tPA/US/MB group ($P=0.12$). Four patients (3.6%) experienced symptomatic intracranial hemorrhage: 2 (5.5%), 1 (2.7%), and 1 patient (2.6%) who received tPA only, tPA/US, and tPA/US/MB, respectively, experienced symptomatic intracranial hemorrhage. At 24 hours, 31%, 41%, and 55% of tPA, tPA/US, and tPA/US/MB improved >4 points in the NIHSS score.

Conclusions—Administration of MBs induces further acceleration of US-enhanced thrombolysis in acute stroke, leading to a more complete recanalization and to a trend toward better short- and long-term outcome. (*Stroke*. 2006;37:425-429.)

Key Words: microbubbles ■ stroke ■ thrombolysis ■ ultrasonography

The Combined Lysis of Thrombus in Brain Ischemia Using Transcranial Ultrasound and Systemic TPA (CLOTBUST) trial has recently demonstrated that continuous 2-MHz transcranial Doppler (TCD) ultrasound (US) monitoring of an acute intracranial artery occlusion safely enhances systemic thrombolysis in stroke patients.¹ US-enhanced thrombolysis is based on the ability of US to induce reversible changes in the fibrin mesh creating microstreams of plasma through the thrombus and accelerating the transport and penetration of

tissue plasminogen activator (tPA) into the clot, resulting in a more complete and faster clot dissolution.²

Microbubbles (MBs) are small air- or gas-filled microspheres with specific acoustic properties that make them useful as US contrast agents for sonographic examinations. In diagnostic US, MBs create an acoustic impedance mismatch between fluids and body tissues, increasing the reflection of sound. Experimental studies have shown that US-accelerated thrombolysis may be further enhanced by administration of

Received September 30, 2005; accepted October 18, 2005.

From the Neurovascular Unit, Department of Neurology, Universitat Autònoma de Barcelona, Hospital Vall d'Hebrón, Barcelona, Spain.

Correspondence to Carlos A. Molina, MD, PhD, Neurovascular Unit, Department of Neurology, Hospital Vall d'Hebrón, Passeig Vall d'Hebrón 119-129, 08035 Barcelona, Spain. E-mail cmolina@vhebron.net

© 2006 American Heart Association, Inc.

Stroke is available at <http://www.strokeaha.org>

DOI: 10.1161/01.STR.0000199064.94588.39

MBs.³⁻⁶ Low-frequency US with high power has been demonstrated to produce cavitation and fluid motion into the thrombus.^{4,5} MBs, by acting as cavitation nuclei, lower the amount of energy needed for cavitation. Application of high-acoustic-pressure US has been shown to induce nonlinear oscillations of MBs, leading to a continuous absorption of energy until the bubbles explode, releasing the absorbed energy.⁷ Thus, US-mediated MB destruction may further accelerate the clot-dissolving effect of US.

The synergic effect of US and MBs on sonothrombolysis has been demonstrated in clinical studies in patients with arteriovenous dialysis graft thrombosis.⁸ However, whether MBs further accelerate US-enhanced systemic thrombolysis in stroke patients remains unknown. Therefore, we sought to investigate the effects of galactose-based MBs on the beginning, degree, and time to maximum completeness of middle cerebral artery (MCA) recanalization during systemic thrombolysis and continuous 2-Hz pulsed-wave TCD monitoring.

Methods

Our target group consisted of patients with acute ischemic stroke admitted within the first 3 hours after symptom onset. Stroke onset was defined as the last time the patient was known to be without any neurological deficit. A total of 226 consecutive patients with a nonlacunar stroke involving the vascular territory of the MCA were evaluated. Of these, 210 (92.9%) underwent urgent carotid US and TCD examinations. Thirty-four patients (15%) were excluded from the study because of insufficient acoustic temporal window or absence of any residual flow in the MCA for TCD examination. We excluded patients who were taking anticoagulants ($n=22$), experienced dramatic spontaneous neurological improvement ($n=28$), or showed early signs of infarction $>33\%$ of the MCA territory on baseline CT ($n=15$). Finally, 111 patients (49.1%) with a documented MCA occlusion on TCD who received intravenous tPA in a standard 0.9-mg/kg dose within <3 hours of symptom onset were included in the study. The first 73 consecutive patients were randomly allocated to be treated with tPA alone (tPA group) or tPA plus 2-hour continuous 2-MHz TCD US monitoring (US group). Randomization was performed at a 1:1 ratio. Most of these patients had taken part in a previous trial of US-enhanced thrombolysis in acute stroke.¹ After the end of this trial and as part of a pilot institutional protocol, 38 consecutive patients were treated with the combination of tPA plus 2-hour continuous 2-MHz TCD monitoring plus 3 boluses of 400 mg/dL of the galactose-based MBs (Levovist), given at 2, 20, and 40 minutes after tPA administration. Informed consent was obtained from all patients or their next of kin. The study protocol was approved by the local ethics committee.

All patients underwent a standard neurological examination, ECG, blood chemistry, extracranial carotid US, and noncontrast CT before treatment. The CT scan was repeated in all patients at 24 to 48 hours (or earlier when rapid neurological deterioration occurred). Trans-thoracic and transesophageal echocardiography and Holter ECG were performed when clinically indicated. With the use of clinical, radiological, cardiac, and US test results, each patient was assessed, by an experienced stroke neurologist, according to modified Trial of Org 10172 in Acute Stroke Treatment (TOAST)⁹ criteria to determine stroke subtype.

Clinical Assessment

We assessed clinical stroke severity at baseline and at 24 hours after symptom onset by means of the National Institutes of Health Stroke Scale (NIHSS) score, which was conducted by a neurologist or a senior neurology resident not involved in sonographic information and video-trained and certified for application of the NIHSS.¹⁰ Early neurological deterioration or improvement was defined as an increase or decrease of ≥ 4 points on the NIHSS score during 24 hours from baseline assessment.¹⁰ An intracranial hemorrhage was consid-

ered symptomatic (SICH) if the patient had clinical deterioration causing an increase of ≥ 4 points on the NIHSS and if the hemorrhage was likely to be the cause of neurological deterioration. Modified Rankin Scale¹¹ (mRS) was used to assess clinical outcome at 90 days. We defined good outcome as mRS score ≤ 2 .

TCD Assessment

A standard TCD examination was performed in the emergency department on admission before tPA administration with the use of 1-channel 2-MHz equipment (TCD 100 mol/L, Spencer Technologies, and DWL Multidop x 4). TCD assessment was performed by 2 certified sonographers with extensive experience in monitoring recanalization in acute stroke. A standard set of diagnostic criteria was applied to diagnose arterial occlusion. Proximal MCA occlusion was defined as the presence of minimal flow signal throughout the MCA at an insonation depth from 45 to 65 mm, accompanied by flow diversion in the ipsilateral anterior cerebral artery and posterior cerebral artery, according to the Thrombolysis in Brain Ischemia (TIBI) grading system.¹² Distal MCA occlusion was defined as blunted or dampened signals (TIBI 2 or 3) in the symptomatic artery with $<30\%$ flow compared with the contralateral MCA and flow diversion signs in ipsilateral neighboring arteries.

After the site of MCA occlusion was identified, continuous monitoring of the residual flow signals was performed with a Marc 500 head frame (Spencer Technologies) to maintain tight transducer fixation and a constant angle of insonation. The depth with the worst residual flow (TIBI 1 to 3) as measured on the TIBI scale was selected for display. Continuous TCD monitoring of recanalization was conducted during the first 2 hours of tPA administration. In patients who received tPA alone, recanalization was assessed by serial brief TCD recordings performed during the first 2 hours after tPA bolus. Changes on TCD in each patient were determined by 1 rater using direct visual control of monitoring display. An additional TCD examination was performed if neurological worsening was detected within the 24 hours after stroke onset.

Recanalization on TCD was diagnosed as partial when blunted or dampened signals appeared in a previously demonstrated absent or minimal flow. Complete recanalization on TCD was diagnosed if the end-diastolic flow velocity improved to normal or elevated values (normal or stenotic signals).¹² The time from tPA bolus to maximum completeness of recanalization (partial or complete) during continuous 2-hour TCD monitoring was recorded. The speed of clot lysis during continuous TCD monitoring was categorized into sudden and slow according to previously published criteria.¹³ No change in the abnormal waveforms indicated that no recanalization had occurred. Recanalization after administration of MBs was defined as a sustained flow improvement that persists after the end of the flow signal enhancement effect of MBs (Figure 1).

Statistical Analysis

The analysis was performed with the use of SPSS 9.0 software (SPSS Inc). Statistical significance for intergroup differences was assessed by the 2-tailed Fisher exact test and Pearson χ^2 test for categorical variables and Student *t* test, Mann-Whitney *U* test, and Kruskal-Wallis test for continuous variables. A level of $P<0.05$ was accepted as statistically significant.

Results

A total of 111 patients (52 men and 59 women) with an acute ischemic stroke attributable to MCA occlusion treated with intravenous tPA within <3 hours of stroke onset were studied. Demographic data, risk factor profile, and baseline clinical findings are shown in the Table. Mean age was 69.6 ± 12.2 years (range, 31 to 87 years). Median NIHSS score on admission was 18 points (interquartile range, 15 to 19 points). The time elapsed between symptom onset and drug administration was 156.4 ± 37.4 minutes (range, 81 to 178 minutes). The door-to-

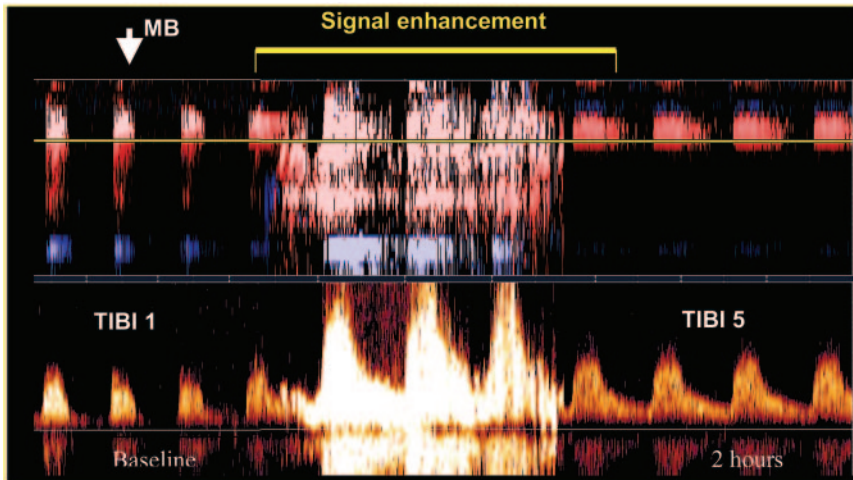


Figure 1. Arterial recanalization after administration of MBs. Spectral waveforms from a proximal left MCA occlusion are shown. Pretreatment TCD showed residual flow (TIBI 1 at an insonation depth of 57 mm). Administration of MBs (arrow) during sonothrombolysis was followed by a sudden complete and sustained recanalization (TIBI 5). Recanalization after administration of MBs was defined as a sustained flow improvement that persists after the end of the flow signal enhancement effect of MBs.

needle time was 62.1±24.1 minutes, ranging from 47 to 109 minutes.

Eighty patients (72%) had a proximal and 31 (28%) a distal MCA occlusion on TCD. Thirty-seven patients (33%) received tPA/US, 38 (34%) received tPA/US/MB, and 36 (32%) were treated with tPA alone. As shown in the Table, baseline stroke severity, time to treatment, location of MCA occlusion, and presence of carotid artery disease were similar among groups.

At 2 hours after tPA bolus, recanalization was seen in 14 (39%), 25 (68%), and 27 patients (71%) in the tPA, tPA/US, and tPA/US/MB groups, respectively (*P*=0.004). Although the overall rate of recanalization at 2 hours was similar (*P*=0.65) between patients who received tPA/US/MB (71%) and patients who received tPA/US (68%), the rate of complete recanalization was significantly (*P*=0.038) higher in the tPA/US/MB group (54.5%) than in the tPA/US (40.8%) and tPA (23.9%) groups (Figure 2).

Demographic Data, Risk Factor Profile, and Baseline Clinical Findings of the Series

Variable	tPA (n=36)	tPA+US (n=37)	tPA+US+MB (n=38)
Age, y	68±11	70±9	68±12
Gender, male	16 (44%)	17 (46%)	15 (39%)
Diabetes mellitus	8 (22%)	10 (27%)	7 (18%)
Hypertension	17 (57%)	18 (48%)	16 (42%)
Baseline NIHSS score	18 (16–19)	18 (15–19)	19 (16–20)
Glucose, mg/dL	156±54	176±94	163±41
SBP, mm Hg	145±21	162±37	159±16
DBP, mm Hg	81±11	83±14	79±17
Platelet count	214±61	245±84	237±65
INR	1.1±0.4	1.0±0.2	0.9±0.1
Proximal occlusion	26 (72%)	28 (76%)	26 (69%)
Severe carotid disease	10 (27%)	12 (32%)	10 (26%)
Door-to-needle time, min	70±14	81±26	72±18
Time to treatment, min	152±33	161±38	158±35

SBP indicates systolic blood pressure; DBP, diastolic blood pressure; INR, international normalized ratio.

The time to beginning of recanalization after tPA bolus was 26±18 minutes in the tPA/US group and 19±12 minutes in the tPA/US/MB group (*P*=0.12). Recanalization started after the first, second, and third MB dose in 8 (29%), 14 (52%), and 5 patients (19%). In the 75 patients who were continuously monitored with TCD, the time from tPA bolus to the maximum completeness of recanalization was 47±32 minutes; the time from tPA bolus to recanalization was significantly (*P*=0.022) shorter in patients who received tPA/US/MB (33±21 minutes) than in those who received tPA/US (56±37 minutes). During the first 2 hours of tPA bolus, 14 patients (13%) recanalized suddenly, 31 (32%) recanalized in a stepwise manner, and 21 (18%) recanalized slowly.

During the first 24 hours of stroke onset, 51 patients (46%) improved, 20 (18%) experienced clinical worsening, and 40 (36%) remained stable. The proportion of patients who achieved clinical improvement at 24 hours tended to be higher (*P*=0.065) in the tPA/US/MB group than in the tPA and tPA/US groups. At 24 hours, 31%, 41%, and 55% of tPA, tPA/US, and tPA/US/MB patients, respectively, improved >4 points in the NIHSS score. The median mRS score at 3 months was 3 points (interquartile range, 1 to 5). The proportion of patients who achieved independence (mRS

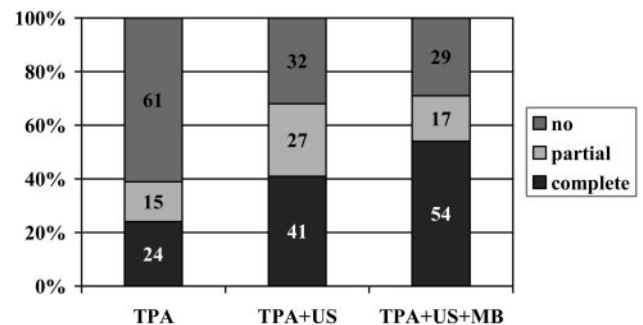


Figure 2. Degree of arterial recanalization at 2 hours of tPA bolus. Although the overall rate of recanalization at 2 hours was similar (*P*=0.65) between patients who received tPA/US/MB (71%) and those treated with tPA/US (68%), the rate of complete recanalization was significantly (*P*=0.038) higher in the tPA/US/MB group (54.5%) than in the tPA/US (40.8%) and tPA (23.9%) groups.

score ≤ 2) at 3 months tended to be higher in the MB group (56%) than in the US (47%) and tPA (32%) groups ($P=0.073$).

Four patients (3.6%) experienced SICH. The occurrence of SICH appeared unrelated to US monitoring or MB administration. Two (5.5%), 1 (2.7%), and 1 patient (2.6%) who received tPA only, tPA/US, and tPA/US/MB, respectively, experienced SICH. Asymptomatic intracranial hemorrhage (HI1-HI2) was detected on control CT in 22 patients (19.8%). Asymptomatic hemorrhages were located in all cases in the deep MCA territory. Six (16%), 7 (19%), and 9 patients (23%) who received tPA only, tPA/US, and tPA/US/MB, respectively, showed asymptomatic hemorrhage on control CT.

Moreover, the administration of 3 boluses of 400 mg/mL of Levovist during tPA infusion was well tolerated in all patients without any complication potentially attributed to MB administration.

Discussion

The present study demonstrates that MB administration safely accelerates US-enhanced thrombolysis, leading to a more complete degree of arterial recanalization, which was reflected in a trend toward better clinical course and long-term outcome in patients receiving MBs during sonothrombolysis.

Experimental and clinical studies have consistently demonstrated the capability of US to potentiate enzymatic thrombolysis.^{1,2,14-16} Administration of MBs may further accelerate the clot-dissolving effect of US by lowering the energy needed for cavitation. Moreover, administration of MBs has been shown to directly harm the clot surface, inducing penetrating forces and shear stress, which may promote high power jetting into the clot.⁷ Tachibana and Tachibana³ first described the effect of echo-contrast agents on clot lysis. These authors observed in an *in vitro* model that the combination of urokinase, low-frequency US (170 kHz), and MBs resulted in an increased rate of fibrinolysis at 60 minutes compared with urokinase plus US or urokinase alone. The bioeffect of US-mediated MB destruction on clot lysis has been demonstrated even in the absence of thrombolytic drugs, with the use of a variety of echo-contrast agents in combination with low-frequency, high-power US.^{4,6,8,17} Recently, in an *in vitro* study a high rate of declotting was observed with the combination of tPA, high-frequency commercially available US (2-MHz), and galactose-based air-filled MBs (Levovist).⁵ The present study demonstrates that the administration of galactose-based MBs during continuous 2-MHz US monitoring may influence the completeness of tPA-induced MCA recanalization. Our findings are in agreement with a recent pilot study by Viguier et al¹⁸ in 8 patients with proximal MCA occlusion, showing a high rate of recanalization (50%) when tPA, MB infusion, and 1-hour continuous transcranial color-coded sonography monitoring were combined. On the other hand, we observed a higher rate of sudden recanalization in the MB group (21%) than in those patients who did not receive MBs, which is in consonance with experimental studies showing that destruction of MBs by US is associated with clot dissolution rather than clot fragmentation.¹⁷

Although US contrast agents have been shown to be safe when given in acute stroke patients,^{19,20} safety information of these agents in the setting of stroke thrombolysis is limited. In the present study the administration of 3 boluses of 400 mg/mL of Levovist was well tolerated in all patients without systemic complications. Moreover, neither continuous 2-MHz US monitoring nor the combination of US plus MBs increased the rate of SICH compared with tPA alone. This is in contrast to the increased rate of SICH observed in stroke patients treated with tPA plus low-frequency (300 kHz) US.²¹ In fact, safety appeared to be better in the 2-MHz US study CLOTBUST (SICH rate 4.8%) compared with the Transcranial Low-Frequency Ultrasound-Mediated Thrombolysis in Brain Ischemia (TRUMBI) trial (SICH rate 35%), which used 300 kHz US.^{1,21} Unlike high-frequency US, low-frequency US application may cause mechanical distortion of the human brain microvessels, leading to vessel disruption. Daffertshofer et al²¹ have hypothesized that reverberations of the long-wavelength US inside the head may produce "hot spots" of US energy. Our observations indicate that US contrast agents may be administered safely during sonothrombolysis with high-frequency US.

Several factors may influence the effect of MBs on sonothrombolysis, including bubble size, stability of the bubble in bloodstream, and the concentration of MBs in the front of clot degradation. Room air-filled MBs are less stable than MBs filled with heavy-molecular-weight gases (eg, sulfur hexafluoride or perfluoropropane), which decrease solubility and improve bubble lifetime.^{17,22} Moreover, these second-generation MBs have much smaller diameters than room air-filled MBs, which improve passage of the pulmonary capillary bed.^{7,22} Furthermore, serial bolus administration may ensure a massive arrival of MBs striking the offensive clot compared with continuous MB infusion. Whether second-generation MBs are more effective than galactose-based air-filled MBs requires further investigation.

This study has certain limitations. Patients were not randomized to receive tPA+US+MBs and were not treated at the same period of time as the other groups. Although baseline characteristics were similar among treatment groups, imbalance cannot be ruled out because of the small sample size. Moreover, the small size precludes the assessment of the effects of MBs among stroke subtypes. Furthermore, because the present study was focused on patients with MCA occlusion, our findings should not be extrapolated to patients with stroke involving other vascular territories. Finally, in our study the assessment of recanalization by the sonographers was unblinded. Therefore, future studies should include an independent evaluation of recanalization with MR or CT angiography.

In conclusion, this exploratory study demonstrates that administration of MBs further enhances US-augmented systemic thrombolysis in acute ischemic stroke, leading to a more complete arterial recanalization and to a trend toward better short- and long-term outcome. Therefore, a multicenter randomized trial of MB-enhanced sonothrombolysis in acute stroke is warranted.

References

1. Alexandrov AV, Molina CA, Grotta JC, Garami Z, Ford SR, Alvarez-Sabin J, Montaner J, Saqqur M, Demchuk AM, Moyé LA, Hill MD, Wojner AW, for the CLOTBUST Investigators. Ultrasound-enhanced thrombolysis for acute ischemic stroke. *N Engl J Med*. 2004;351:2170–2178.
2. Francis CW, Blinc A, Lee S, Cox C. Ultrasound accelerates transport of recombinant tissue plasminogen activator into clots. *Ultrasound Med Biol*. 1995;21:419–424.
3. Tachibana K, Tachibana S. Albumin microbubble echo-contrast material as an enhancer for ultrasound accelerated thrombolysis. *Circulation*. 1995;92:1148–1150.
4. Mizushige K, Kondo I, Ohmori K, Hirao K, Matsuo H. Enhancement of ultrasound-accelerated thrombolysis by echo-contrast agents: dependence on microbubble structure. *Ultrasound Med Biol*. 1999;25:1431–1437.
5. Cintas P, Nguyen F, Boneu B, Larrue V. Enhancement of enzymatic fibrinolysis with 2-MHz ultrasound and microbubbles. *J Thromb Haemost*. 2004;2:1163–1166.
6. Culp WC, Porter TR, Lowery J, Xie F, Robertson PK, Marky L. Intracranial clot lysis with intravenous microbubbles and transcranial ultrasound in swine. *Stroke*. 2004;35:2407–2411.
7. Dijkmans PA, Juffermans LJM, Musters RJP, van Wamel A, ten Cate FJ, van Gilst W, Visser CA, de Jong N, Kamp O. Microbubbles and ultrasound: from diagnosis to therapy. *Eur J Echocardiography*. 2004;5:245–256.
8. Xie F, Tsutsui JM, Lof J, Unger EC, Johanning J, Culp WC, Matsunaga T, Porter TR. Effectiveness of lipid microbubbles and ultrasound in de clotting thrombosis. *Ultrasound Med Biol*. 2005;31:979–985.
9. Albanese MA, Clarcke WR, Adams HP Jr, Woolson RF. Ensuring reliability of outcome measures in multicenter clinical trials of treatments for acute ischemic stroke: the program developed for the Trial of Org 10172 in Acute Stroke Treatment (TOAST). *Stroke*. 1994;25:1746–1751.
10. Lyden P, Brott T, Tilley B, Welch KMA, Mascha EJ, Levine S, Haley EC, Grotta J, Marler J, and the NINDS t-PA Stroke Study Group. Improved reliability of the NIH Stroke Scale using video training. *Stroke*. 1994;25:2220–2226.
11. Van Swieten JC, Koudstaal PJ, Visser MC, Schouten HJA, van Gijn J. Interobserver agreement for the assessment of handicap in stroke patients. *Stroke*. 1988;19:604–607.
12. Burgin WS, Malkoff M, Demchuk AM, Felberg RA, Christou I, Grotta JC, Alexandrov AV. Transcranial Doppler ultrasound criteria for recanalization after thrombolysis for middle cerebral artery stroke. *Stroke*. 2000;31:1128–1132.
13. Alexandrov AV, Burgin SW, Demchuk AM, El-Mitwalli A, Grotta JC. Speed of intracranial clot lysis with intravenous tissue plasminogen activator therapy: sonographic classification and short-term improvement. *Circulation*. 2001;103:2897–2902.
14. Behrens S, Spengos K, Daffertshofer M, Schroeck H, Dempfle CE, Hennerici M. Transcranial ultrasound-improved thrombolysis: diagnostic vs therapeutic ultrasound. *Ultrasound Med Biol*. 2001;27:1683–1689.
15. Eggers J, Koch B, Meyer K, König I, Seidel G. Effects of ultrasound on thrombolysis of middle cerebral artery occlusion. *Ann Neurol*. 2003;53:797–800.
16. Daffertshofer M, Hennerici M. Ultrasound in the treatment of ischemic stroke. *Lancet Neurol*. 2003;2:283–290.
17. Unger EC, Matsunaga TO, McCreery T, Schumann P, Sweitzer R, Quigley R. Therapeutic applications of microbubbles. *Eur J Radiol*. 2002;42:160–168.
18. Viguier A, Petit R, Rigal M, Cintas P, Larrue V. Continuous monitoring of middle cerebral artery recanalization with transcranial color-coded sonography and Levovist. *J Thromb Thrombolysis*. 2005;19:55–59.
19. Seidel G, Albers T, Meyer K, Wiesmann M. Perfusion harmonic imaging in acute middle cerebral artery infarction. *Ultrasound Med Biol*. 2003;29:1245–1251.
20. Baumgartner RW. Transcranial color duplex sonography in cerebrovascular disease: a systematic review. *Cerebrovasc Dis*. 2003;16:4–13.
21. Daffertshofer M, Gass A, Ringleb P, Sitzer M, Sliwka U, Els T, Sedlaczek O, Koroshetz WJ, Hennerici MG. Transcranial low-frequency ultrasound-mediated thrombolysis in brain: increased risk of hemorrhage with combined ultrasound and tissue plasminogen activator: results of a phase II clinical trial. *Stroke*. 2005;36:1441–1446.
22. Nanda NC, Schlieff R, Goldberg BB. *Advances in Echo Imaging Using Contrast Enhancement*. 2nd ed. Dordrecht, Netherlands: Kluwer Academic Publishers; 1997.